

## CASE REPORT

# Retropharyngeal abscess, submandibular abscess, and regio colli abscess with bronchopneumonia in a 2.5-month-old boy

Irhamna Yusra, Finny Fitry Yani

Department of Pediatric, RSUP M. Djamil

**Correspondence:** Irhamna Yusra; email: [irhamna.yusra@yahoo.com](mailto:irhamna.yusra@yahoo.com)

### Abstract

Deep neck space infections (DNSIs) in pediatric require more intimate management because of their rapidly progressive nature. Delay in diagnosis and treatment may lead to life-threatening complications. **Objective:** To report DNSIs as one of emergency case in children. Early diagnosis and immediate management can decrease morbidity and mortality rate in children. **Case:** A case of a 2.5-month-old boy with chief complain breathlessness due to deep neck space infections and bronchopneumonia. Patient was getting better after surgical drainage. **Conclusions:** It most commonly occurs in children younger than four years of age having medical history of streptococcal pharyngitis, rarely as a complication of recent trauma, odontogenic infection or extension of vertebral osteomyelitis. Management often consists of antimicrobial therapy and surgical drainage. With the cooperation of ENT specialist and pediatrician/pediatric infectious disease specialist. Management in PICU is mandatory due to high risk of complications.

**Keywords:** retropharyngeal abscess; submandibular abscess; colli; bronchopneumonia

### Abstrak

Abses leher dalam pada pasien anak memerlukan tatalaksana yang lebih teliti dikarenakan penyakit ini yang progresif. Keterlambatan pada diagnosis dan terapi dapat menyebabkan komplikasi yang membahayakan nyawa pasien. **Tujuan:** Melaporkan abses leher dalam sebagai salah satu penyebab kegawatan nafas pada anak yang memerlukan penanganan yang cepat. **Diagnosis dini dan penatalaksanaan segera kasus abses leher dalam dapat menurunkan angka morbiditas dan mortalitas pada anak.** **Kasus:** Dilaporkan seorang bayi laki-laki 2,5 bulan dengan keluhan sesak nafas karena abses leher dalam dan bronkopneumonia. Pasien perbaikan setelah dilakukan drainase abses. **Simpulan:** Penyakit ini paling banyak terjadi pada pasien kurang dari 4 tahun yang mempunyai riwayat medis faringitis streptokokus, jarang akibat trauma, infeksi gigi atau perluasan dari osteomyelitis vertebra. Tatalaksana terdiri dari terapi antibiotik dan drainase abses dengan kerja sama yang baik antara dokter THT dan Anak. Perawatan intensif dibutuhkan dikarenakan tingginya risiko komplikasi.

**Kata kunci:** abses retrofaring; abses submandibular; coli; bronkopneumonia

## INTRODUCTION

Deep neck space infections (DNSIs) can occur at any age but the pediatric deep neck infections require more intimate management because of their rapidly progressive nature. Delay in diagnosis and treatment may lead to life-threatening complications. The incidence and morbidity of DNSIs has been significantly reduced with the introduction of antibiotic therapy. Concurrent abscess in distinct neck spaces has rarely been reported in healthy children.<sup>1</sup>

Retropharyngeal abscess is suppurative infection located in retropharyngeal space between the pharynx and the cervical vertebrae, which can be extending through upper parts of mediastinum. It most commonly occurs in children younger than four years of age having medical history of streptococcal pharyngitis, rarely as a complication of recent trauma, odontogenic infection or extension of vertebral osteomyelitis.<sup>2</sup>

Most frequently causative agents are *S. aureus* and group A  $\beta$ -haemolytic streptococcus (GABHS, *Streptococcus pyogenes*), followed by anaerobic bacteria *Fusobacterium* and *Bacteroides*. Also, *Haemophilus influenzae*, *Klebsiella sp*, *Mycobacterium tuberculosis* and *M. avium-intracellulare* can be found.<sup>2</sup> In young infants, nasopharyngeal infection may be common, but secondary retropharyngeal abscess formation is rare. In the event that a retropharyngeal abscess- does develop, Group B

*Streptococcus* and *Staphylococcus aureus* are common pathogens in these infants. *Staphylococcus aureus* is a very common source of superinfection after respiratory viral infection due to bacterial-viral interactions.<sup>3,4</sup> The patient is frequently febrile, appears toxic, inappetence, irritable, having respiratory distress. Diagnosis can almost exclusively be given with comprehensive examination and completed with radiographic visualisation of expended retropharyngeal space and presence of air in prevertebral soft tissue. Loss of physiological cervical lordosis can also be seen.<sup>2</sup>

Retropharyngeal abscess is a result of suppuration of paramedian lymph nodes following an upper respiratory infection.<sup>1</sup> Management often consists of antimicrobial therapy and surgical drainage.<sup>5</sup> With the cooperation of ENT specialist and pediatrician/pediatric infectious disease specialist. Management in PICU is mandatory due to high risk of complications.<sup>2</sup>

## CASE

Patient M, 2.5 months old, referred from South Solok District Hospital with suspicion of hygroma colli, bronchopneumonia and sepsis with chief complain more breathlessness in the last 1 week before admission. Patient has fever in the last 20 days before admission, intermittent, high, no shivering, no sweating, and no seizure. Breathlessness since 18 days before admission and more breathlessness since 1 week before admission. Cough since 2

weeks before admission, no cold. There was swollen on the right side of neck since 1 week ago, firstly as big as quail eggs, then the size was bigger, as big as tennis ball. No vomit. There was no history of choking. No history contact with chronic cough patient. No history contact with sudden death poultry. No history of trauma on neck. History of insect bite was denied by parents. Micturition and defecation in normal limit. Patient was referred from South Solok District Hospital with suspicion of hygroma colli, bronchopneumonia, and sepsis; and had been hospitalized for 20 days and had been got CPAP for 7 days, meropenem, ranitidine, and paracetamol. The patient didn't suffer this disease before. There is no family suffering similar illness like this, no family member with chronic cough or got anti tuberculosis drugs. Patient live in semi-permanent house with poor hygiene and sanitation.

In physical examination general appearance severely ill, alert, blood pressure 85/45 mmHg, pulse rate 116x/minute, respiratory rates 56x/minute, body temperature 38.8°C. Body weight was 3.2 kgs (Z score -2 s/d -3 SD), body length 58 cm (Z score -2 s/d -3 SD), and weight per height was Z score -2 s/d -3 SD. It was interpreted as undernourished. His skin was warm. Lymph node was palpable on region right submandibular, size 1.5x1.5x1.5 cm. Symmetric round head. Head circumference was 41 cm (normocephal based on standard Nellhaus). Fontanel was opened, hair was black and not easily

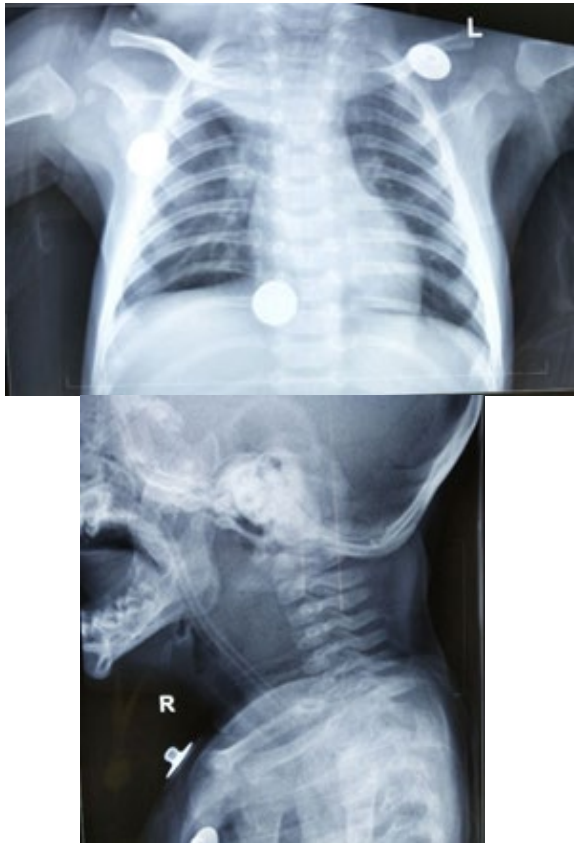
pulled out. There was cystic mass on the right side of neck, size 4x3x2 cm, fluctuating, no hyperemic. Conjunctiva was anemic, sclera was not icteric, the pupils were normal. Ears and nose were normal. Tonsil T1-T1 hyperemic and faring was hyperemic, no crypti and no detritus. Jugular venous pressure 5-0 cmH<sub>2</sub>O. Chest was symmetrical, epigastria retraction, there was rales on both lungs, no wheezing. Heart sound was regular and no additional sound. Enlargement of liver and spleen was not present. Genital pubertal stage A1P1G1. The extremities were warm with good perfusion, physiological reflexes were normal, no pathological reflexes.

Laboratory result revealed that hemoglobin level was 9.4 gr/dl, leucocyte 20,600/mm<sup>3</sup>, differential count 0/0/1/74/25/0, platelet 145,000/mm<sup>3</sup>. MCV 91.1 fl, MCH 27.6 pg, MCHC 32%. Na 146 mmol/l, K 3.7 mmol/l, Ca 10.1 mg/dl, Blood Glucose Random 108 mg/dl. Blood gas analysis pH=7.36, pCO<sub>2</sub>=50.2, pO<sub>2</sub>=29.2, HCO<sub>3</sub>=28.7, BE=3.9, SO<sub>2</sub>=49.1 (hypoxemia, mixed with venous blood). Urine and stool were in normal limit.

Patient diagnosed with suspect hygroma colli, differential diagnosed with abscess region colli, bronchopneumonia and normocytic normochromic anemia due to infection. Patient treat with oxygen nasal supplementation 2 L/minute, IVFD Kaen 1B, meropenem, ampicillin, and paracetamol.

Patient was performed chest x-ray with result suitable with bronchopneumonia and cervical x-ray with result thickening at

retropharyngeal, retrolaryngeal, and retrotracheal, due to suspect hygroma colli and with differential diagnoses an abscess.



**Figure 1.** Thorax and Cervical X Ray

In second day of hospitalization, patient still breathlessness and look dyspnea. No fever, no seizure, no vomiting, micturition and defecation was in normal limit. Patient was alert with pulse rate was 118x/minute, respiratory rate was 42x/minute (dyspnea), body temperature 36.8°C. There was cystic mass on the right side of neck, size 4x3x2 cm, fluctuating, no hyperemic. Conjunctiva was not anemic and the sclera was not icteric, there was rales on both of lung, cor has no murmur, regular rhythm. Stomach was not distended; peristaltic sound was positive. Warm acral, CRT <2 second. Consultation of ENT Department: obstruction

impending, bronchopneumonia in therapy, dyspnea due to obstruction, suspicion of hygroma colli with differential diagnoses right deep neck; advice: intubation, collective care with ENT department sub larynx and pharynx. Impression: dyspnea due to suspicion of obstruction of hygroma colli with differential diagnoses abscess regio colli, bronchopneumonia. Planning: intubation, performed ventilator PSIMV modes PIP 11 PEEP 4 RR 30 FiO<sub>2</sub> 50%, check blood gas analysis after setting ventilator. Others therapy was continued. Result of blood gas analysis: pH=7.47, pCO<sub>2</sub>=41.9, pO<sub>2</sub>=82.1, HCO<sub>3</sub>=26.8, BE=2.1, SO<sub>2</sub>=92.8 (in normal limit).

In third day of hospitalization patient still intubated with ventilator modes PSIMV PIP 11 PEEP 4 RR 30 FiO<sub>2</sub> 50%. No fever, no seizure, no vomiting, micturition, and defecation was in normal limit. Patient was alert with pulse rate was 100x/minute, respiratory rate was 35x/minute, body temperature 36.8°C. There was cystic mass on the right side of neck, size 4x3x2 cm, fluctuating, no hyperemic. Conjunctiva was anemic and the sclera was not icteric, air entry on left and right was same, rales was present on both of lungs. Stomach was not distended; peristaltic sound was positive. Warm acral, CRT <2 second. Planning: Blood gas analysis follow up. Result pH=7.43, pCO<sub>2</sub>=40.8, pO<sub>2</sub>=144.6, HCO<sub>3</sub>=27.5, BE=3.6, SO<sub>2</sub>=99% (hyperoxemia), derivation of FiO<sub>2</sub> 50% to 40%.

In fourth day of hospitalization patient still intubated with ventilator modes PSIMV PIP

11 PEEP 4 RR 30 FiO<sub>2</sub> 40%. No fever, no seizure, no vomiting, micturition, and defecation was in normal limit. Patient was alert with pulse rate was 100x/minute, respiratory rate was 35x/minute, body temperature 36,8 0C. There was cystic mass on the right side of neck, size 4x3x2 cm, fluctuating, no hyperemic. Conjunctiva was anemic and the sclera was not icteric, air entry on left and right was same, rales was present on both of lungs. Stomach was not distended; peristaltic sound was positive. Warm acral, CRT <2 second. Patient was also performed aspiration by ENT department, there was pus ±12 cc, the color was yellow greenish, advice to performed incision and exploration in general anaesthesia. Impression: suspicion of retropharyngeal abscess and infected lymphadenitis colli region Planning: Blood gas analysis follow up. Result pH=7.55, pCO<sub>2</sub>=31.8, pO<sub>2</sub>=153.1, HCO<sub>3</sub>=28.4, BE=7 SO<sub>2</sub>=99.6% (respiratory alkalosis with hyperoxemia), try to wean patient from ventilator, consultation to anesthesiology department pro incision and exploration in general anesthesia.

In fifth day of hospitalization patient had been performed incision and exploration in operation room, there was 50 cc pus exited from colli and submandibular regions. There was 0,5 cc pus exited from retropharyngeal region, then patient transferred to PICU. In PICU patient was still intubated with ventilator modes PSIMV PIP 11 PEEP 4 RR 25 FiO<sub>2</sub> 30%. No fever, no seizure, no vomiting, micturition and defecation was in normal limit. Patient

was alert with pulse rate was 100x/minute, respiratory rate was 40x/minute, body temperature 36.8°C. The right side of neck was closed by bandage. Conjunctiva was anemic and the sclera was not icteric, air entry on left and right was same, rales was present on both of lungs. Stomach was not distended; peristaltic sound was positive. Warm acral, CRT <2 second. Impression: post incision and exploration retropharyngeal abscess with colli region expansion. Planning: weaning ventilator, check routine hematology and electrolyte post operation, culture pus. Result: Hb 5.5 gr/dl, leucocyte 6,360/mm<sup>3</sup>, platelet 72,000/mm<sup>3</sup>, Na 134 mmol, K 3.4 mmol/l, Ca 9.2 mg/dl. Anemia and thrombocytopenia due to sepsis. Planning: PRC transfusion, no need platelet transfusion due to there was no bleeding. KCL 3x75 mg po.

In sixth day until nine day of hospitalization Patient had been weaning from ventilator, now patient with oxygen nasal 2 l/i, no fever, no seizure, no vomiting, micturition and defecation was in normal limit. PRC transfusion had been done. Patient was alert with pulse rate was 100x/minute, respiratory rate was 30x/minute, body temperature 36,8 0C. The wound on the right side of neck was good, no pus, no blood. Conjunctiva was not anemic and the sclera was not icteric, rales was decrease on both of lungs. Stomach was not distended; peristaltic sound was positive. Warm acral, CRT <2 second. Result of pus culture: Staphylococcus aureus sensitive with meropenem, ampicillin, gentamicin,

ciprofloxacin, vancomycin, and tetracycline. Impression: post incision and exploration retropharyngeal abscess with colli region expansion, bronchopneumonia was improvement.

Patient was discharged from hospital at twelve day of hospitalization with no fever, no breathlessness. Patient controlled to pediatric outpatient clinic 1 weeks after hospitalization with stable condition.

## DISCUSSIONS

We present a case of 2.5-month-old boy with retropharyngeal abscess, submandibular abscess, and regio colli abscess due to staphylococcus aureus and bronchopneumonia. Diagnose was made based on history, physical examination and supporting investigation.

In this case we present a 2.5-month-old boy infant who has had a two-week lasting respiratory tract infection and eventually developed deep neck infection at a very early age. As far as we found in the literature, there are rare cases of development of retropharyngeal abscess at this early age.<sup>2</sup> Predominantly male (2:1) with seventy percent of the patients are younger than six years of age.<sup>6</sup>

Infections of upper respiratory tract are common in infants and young children, usually presented with cough, coryza and poor oral intake. Dramatical respiratory distress (suprasternal and subcostal retractions, grunting) with drooling, dysphagia, odynophagia, cervical lymphadenopathy, torticollis, unilateral

neck and pharyngeal wall swelling is mostly present in children with deep neck infections. On anamnesis in our patient, there was cough, coryza, poor oral intake, unilateral neck swelling that suggest there was a deep neck infection.<sup>2</sup>

Cervical bacterial infection may result from endogenous oropharyngeal, nasal or dental flora or skin infections on the scalp or face or from person-to-person spread by airborne droplets. Prompt diagnosis and treatment of bacterial cervical infection are important due to the presence of so many vital structures in proximity. The upper anterior neck was the most commonly involved anatomic area, followed by the submandibular and middle anterior neck. Similarly, upper anterior deep cervical and submandibular locations were the most commonly involved areas. Since the submandibular and deep anterior and posterior cervical nodes receive most of the lymphatic drainage of the head and neck, these nodes are involved in more than 80% of children who develop infectious cervical adenitis.<sup>7</sup> Infection is the most common cause of neck swelling in the pediatric population, with lymphadenitis being the predominant etiology. Other potential causes of neck swelling include a variety of congenital, inflammatory, benign, and malignant lesions.<sup>8</sup> In our case, patient with submandibular lymphadenitis.

Generally, the clinical course of a retropharyngeal abscess includes fever, neck swelling, drooling, and swallowing difficulties, and is typically associated with

prior upper respiratory tract infection and a history of trauma caused by foreign bodies. As the abscess grows, it usually causes significant respiratory distress, particularly in young children. Our patient displayed of these classical presentations and experience any respiratory distress.<sup>9</sup> Retropharyngeal abscess can present as torticollis in 67% of cases due to spasm of the neck muscles. Indeed, a recently published report described a rare case of retro-pharyngeal abscess complicated by torticollis in a 4-year-old girl. Retropharyngeal abscesses can also severely obstruct the airway. Our patient showed signs of airway obstruction with dyspnea and need intubation.<sup>7</sup>

Radiological evaluation is essential before the surgical intervention in order to objectify the extension of the inflammatory process.<sup>2</sup> When establishing a diagnosis of retropharyngeal abscess, the lateral X-ray is helpful. In this case patient was performed Cervical X-ray with result there was thickening at retropharyngeal, retrolaryngeal and retrotracheal space.<sup>9</sup>

Firstly, the diagnosis of patient still in doubt, because possibility hygroma colli. Hygroma colli is congenital malformation of the lymphatic system that manifests itself as a soft, benign and painless mass. Usually hygroma colli was found since birth.<sup>10</sup> This was difference with our patient that the mass was appeared when patient on 2 months old. To exclude the diagnosis of hygroma colli, ENT department performed aspiration on mass. The pus was present from mass. So

that, the impossibility the hygroma colli was sure.

Most frequently causative agents are *Staphylococcus aureus* and group A  $\beta$ -haemolytic streptococcus (GABHS, *S. pyogenes*), followed by anaerobic bacteria *Fusobacterium* and *Bacteroides*. *Influenzae*, *Klebsiella* sp., *Mycobacterium tuberculosis* and *M. avium-intracellulare* can be found.<sup>2,11</sup> Similarly with our patient, the result of pus culture was *Staphylococcus aureus*.

In terms of treatment, the decision of whether to apply medical or surgical management depends on several factors, including the general condition of the child, the size of the abscess, potential complications arising from the abscess, and surgical accessibility. Several authors have suggested using surgery only when patients do not respond to medical treatment (e.g. intravenous antibiotics).<sup>9</sup>

Due to high risk of serious complications septic shock, spontaneous rupture of the abscess with aspiration pneumonia, carotid artery erosion, suppurative thrombophlebitis of internal jugular veins and mediastinitis, quick and aggressive treatment in the intensive care unit is mandatory. Multidisciplinary work-out is desirable and necessary for complete diagnostic and therapeutic management, which was clearly demonstrated in our case report.<sup>2</sup>

With the cooperation of ENT specialist and pediatrician/pediatric infectious disease specialist, treatment consists of a

combination of abscess incision and parenteral antibiotic administration. Management in PICU is mandatory due to high risk of complications.<sup>2</sup> In our case, patient was care with ENT department and PICU pediatrician also. Treating a retropharyngeal abscess, especially in children is challenging. Mortality was reported as high as 6.7 to 15 percent in younger age group before the wide usage of broad-spectrum antibiotic. In early abscess, some patient may respond well with intravenous antibiotic alone.<sup>6</sup> Patient got meropenem and ampicillin, that were suitable with pus culture of patient.

In this patient, securing an airway before surgery was in the dilemma. Oral

intubation may either fail or it may rupture the abscess causing aspiration to the lung as the airway is likely to be distorted with oedema and laryngeal displacement.<sup>6</sup> The patient can wean from ventilator after operation and in stable condition.

## CONCLUSIONS

Retropharyngeal abscess is suppurative infection located in retropharyngeal space between the pharynx and the cervical vertebrae, which can be extending through upper parts of mediastinum. Management often consists of antimicrobial therapy and surgical drainage with the collaboration of ENT specialist and pediatrician/pediatric infectious disease specialist.

## REFERENCES

1. Raghani MJ, Raghani N. Bilateral deep neck space infection in pediatric patients: review of literature and report of a case. *J Indian Soc Pedod Prev Dent.* 2015; 33(1):61-5. doi: [10.4103/0970-4388.149009](https://doi.org/10.4103/0970-4388.149009). [PubMed]
2. Katavić M, Štefanović IM, Vrsalović R, Zlatić-Glogoški M, Tešović G, Baudoin T. Retropharyngeal Abscess in a Four Month Old Female Infant-Case Report. *International Journal of Pediatrics & Neonatal Care.* 2016; 2:121. doi: [10.15344/2455-2364/2016/121](https://doi.org/10.15344/2455-2364/2016/121).
3. Shin JH1, Sung SI, Kim JK, Jung JM, Kim ES, Choi SH, et al. Retropharyngeal abscess coinfecting with *Staphylococcus aureus* and *Mycobacterium tuberculosis* after rhinoviral infection in a 1-month-old infant. *Korean J Pediatr.* 2013; 56(2):86-9. doi: [10.3345/kjp.2013.56.2.86](https://doi.org/10.3345/kjp.2013.56.2.86). [PubMed]
4. Coticchia JM, Getnick GS, Yun RD, Arnold JE. Age-, site-, and time-specific differences in pediatric deep neck abscesses. *Arch Otolaryngol Head Neck Surg.* 2014; 130(2):201-7. doi: [10.1001/archotol.130.2.201](https://doi.org/10.1001/archotol.130.2.201). [PubMed]
5. Dolan K, Estrellado W. Retropharyngeal Abscess in a Medically Complex Child Presenting With Respiratory Failure. *Chest (Fellow Case Report Poster- Pediatrics).* 2016; 150(4S):954A. doi: [10.1016/j.chest.2016.08.1057](https://doi.org/10.1016/j.chest.2016.08.1057).
6. Hui LR, Selamat M, Hamid Z, Abu Bakar AZ, Thomas TH. Retropharyngeal Abscess in Child-Dilemma in Airway Management. *Ann Otolaryngol Rhinol.* 2016; 3(11):1141. [Abstract/FREE Full-Text].



7. Cengiz AB, Kara A, Kanra G, Seçmeer G, Ceyhan M, Özen M. Acute neck infections in children. The Turkish Journal of Pediatrics. 2014; 46(2):153-8. [[Abstract/FREE Full-Text](#)].
8. Skoog H, Clark DW. Submandibular neck mass in a newborn. Proc (Bayl Univ Med Cent). 2017; 30(4):461–462. [[PMC free article](#)]
9. Mydam J, Thiagarajan P. A nine month old child with retropharyngeal abscess secondary to mastoid abscess presenting as torticollis: a case report. Cases J. 2009; 2:6460. doi: [10.4076/1757-1626-2-6460](https://doi.org/10.4076/1757-1626-2-6460). [[PMC free article](#)].
10. Mirza B, Ijaz L, Saleem M, Sharif M, Sheikh A. Cystic hygroma: an overview. J Cutan Aesthet Surg. 2010; 3(3):139-44. doi: [10.4103/0974-2077.74488](https://doi.org/10.4103/0974-2077.74488). [[PMC free article](#)].
11. Smith MM, Heubi CH. Infections of the Neck and Pharynx in Children. Curr Treat Options Peds. 2018; 4:211. doi: [10.1007/s40746-018-0127-y](https://doi.org/10.1007/s40746-018-0127-y).